

# Flap Surgery – *A Breakthrough*

Tim Wang, Imperial College London

*Flap - A unit of tissue transferred from a donor site with its blood supply to a recipient site*

## Pre-Flap Surgery

Traditionally, after excising large amounts of tumour tissue, large defects could only be closed by direct suturing. Size of the defect limited operations, the results were unsatisfactory and surgeons experimented with different methods of reducing wound tension which compromises the blood supply.

## Origins

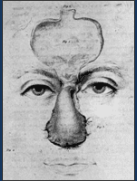

Fig. 1 Indian method of rhinoplasty <sup>1</sup>

Flap surgery dates back to 600 B.C., when Indian surgeon Sushruta Samita described nasal reconstruction using a forehead or cheek flap. (Fig.1) Flap surgery only reached Europe in 1779 when Francois Chopart employed a flap from the chin of a patient to close a defect in his lower lip.

Large defects could now be closed satisfactorily using adjacent or distant tissue.

## Process

The process can be explained using an example of an interpolated local flap. (Fig 2.) A suitable donor site is identified adjacent to the recipient site. A flap is initially outlined and elevated. (A) Donor site is closed and pedicle is attached to recipient area. (B) Pedicle is divided once flap has revascularized. (C)

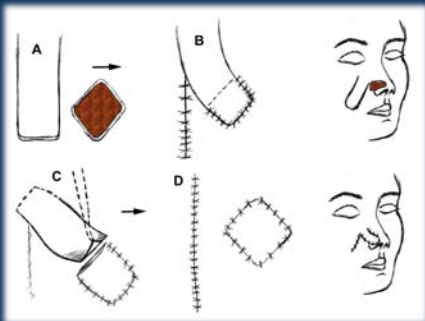


Fig 2. An interpolated flap <sup>2</sup>

## Classification

Flaps can be broadly classified by three categories: <sup>2</sup>

1. Blood supply
  - Unnamed
  - Recognized Artery
2. Tissue
  - One Type
  - Multiple Types
3. Donor Location
  - Adjacent
  - Non-contiguous

- **Random Flap**  
- **Axial Flap**

- **Skin/Fascia/Muscle**  
- **Composite Flap**

- **Local Flap**  
- **Distant Flap**

## Principles

Complications of flap surgery can be catastrophic. The following basic principles of flap surgery have developed over the years to optimize outcome and minimize morbidity. <sup>3</sup>

### Principle I: Replace Like With Like

*Tissue should be replaced in kind; bone for bone, muscle for muscle and hairless skin for hairless skin.*

### Principle II: Think in Terms of Units

*The head for example is composed of different units; scalp, face and ears. Each of these units can be subdivided into subunits of various shapes. It is often better to convert a partial-unit defect to a whole unit defect prior to reconstruction.*

### Principle III: Always Have a Back-Up Plan

### Principle IV: Steal From Peter to Pay Paul

*Flap surgery is like robbing the bank – getting something for nothing. But this only holds true if the donor site can afford it and closure is achieved without tension.*

### Principle V: Never Forget the Donor Area

*The primary and secondary defects need to be considered equally and another reconstructive option considered if the cost is too great.*

## Development

All initial flaps were local random flaps which were manipulated in different orientations. However, if a flap was too long in relation to the width of its base, the risk of necrosis increased significantly. Since then, more and more axial flaps are employed. Recently, re-anastomosing donor vessels to recipient vessels enabled the use of free flaps.

## Future Importance

Microsurgery uses the operating microscope to re-anastomose nerves and blood vessels. It is an important tool in achieving complex reconstructions using free flaps from distant sites. (Fig 3.)

Flap surgery will continue to form the backbone of a surgeon's armamentarium for the repair of cutaneous defects.

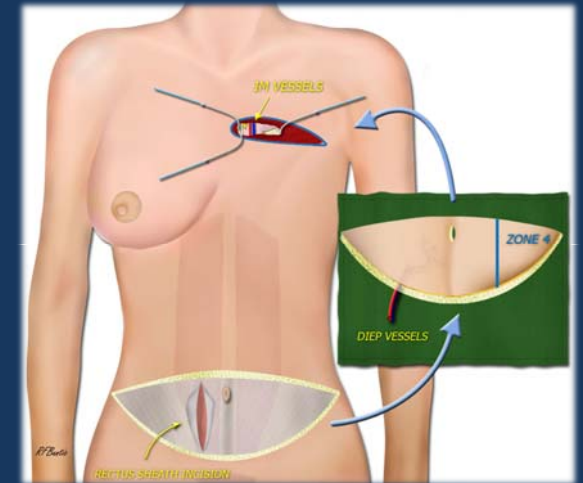


Fig 3. DIEP (Deep inferior epigastric artery perforator) Microsurgical Breast Reconstruction <sup>4</sup>

References:

- 1) The Face Trust <http://www.thefacetrust.org/history.asp> December 2008
- 2) Chrysoulo MT. Flaps – Classification EMedicine <http://emedicine.medscape.com/article/128474-overview> 2008
- 3) Santoni-Rugliu P. History of Plastic Surgery – Skin Flaps. Springer 2007.
- 4) Buntic RF. DIEP Microsurgical Breast Reconstruction [www.microsurgeon.org/images/dieptrimmed.jpg](http://www.microsurgeon.org/images/dieptrimmed.jpg)